

Spectrum of histopathological lesion in surgically removed appendix

Hanish Kumar Chawda^{1*}, Arun T. Miskin², V.D. Dombale³.

¹P G Student, Department of Pathology, S.N. Medical College & Hospital, Navanagar, Bagalkot, Karnataka, India

²Professor, Department of Pathology, S.N. Medical College & Hospital, Navanagar, Bagalkot, Karnataka, India

³Professor & Head, Department of Pathology, S.N. Medical College & Hospital, Navanagar, Bagalkot, Karnataka, India

Received 01 May 2015; Accepted 21 May 2015

ABSTRACT

Background and objectives: Appendicitis is the most common intra-abdominal condition requiring emergency surgery, with a 7% lifetime risk. We have prospectively studied the histomorphology of different disease processes affecting the appendix and correlated the clinical diagnosis with the histopathological findings.

Methods: The appendicectomies done primarily for appendicular pathology, received at histopathology section of our department were included and those resected along with hysterectomy and hemicolectomy procedures were excluded from this study.

Results: A total of 420 specimens were analyzed. 256 (60.95%) were males and 164 (39.05%) females. The histopathological examination showed acute inflammation in 241 (57.32%), chronic inflammation in 166 (39.52%), granulomatous in 3 (0.71%), tumor and tumor like lesions in 9 (2.14%), diverticulosis in one (0.2%), were found in appendix. Parasites were found in 6 (1.42%), mucocoele in four (0.95%) and carcinoids in 4 (0.95%) and mucinous adenocarcinoma in one (0.23%). Clinico-pathological correlation for acute appendicitis was 64.15% and for recurrent appendicitis was 51.93%.

Conclusion: Despite the decline in incidence of appendicitis in recent decades, the vermiform appendix continues to be frequently encountered surgical pathology specimen. Our knowledge about diseases of appendix including appendicitis, the most common disease, is far from complete. This organ therefore remains worthy of careful and systematic study both by the clinician and the pathologist.

Keywords: Appendicitis; appendicectomy; histopathology of appendix.

INTRODUCTION

The appendix is a normal true diverticulum of the caecum that is prone to acute and chronic inflammation. Acute appendicitis is most common in adolescents and young adults, but may occur in any age group. The lifetime risk for appendicitis is 7%; males are affected slightly more often than females. Despite the prevalence of acute appendicitis, the diagnosis can be difficult to confirm preoperatively and may be confused with mesenteric lymphadenitis (often secondary to unrecognized Yersinia infection or viral enterocolitis), acute salpingitis, ectopic pregnancy, mittelschmerz (pain caused by minor pelvic bleeding at the time of ovulation), and Meckel diverticulitis.¹

Appendicitis is the most common – intra - abdominal condition requiring emergency surgery.² The incidence of acute appendicitis roughly parallels that of lymphoid development, with peak incidence in the late teens and twenties. Obstruction of the lumen is the dominant factor

in acute appendicitis, and although fecoliths and lymphoid hyperplasia are the usual cause of obstructions, some unusual factors could also be involved.^[3,4]

Urgent appendicectomy is the accepted treatment to prevent perforation, which is the single most important factor in morbidity and mortality. This has markedly reduced the morbidity but has led to an increase in diagnostic error rate.⁵

Despite the more recent advances in the laboratory tests, radiological examination, sonography, laparoscopy, endoscopy all of which have claimed a place in the diagnosis of specific appendiceal pathologies, have had little effect on overall accuracy of diagnosis and management of disease processes in the organ.⁶

Hence, this organ remains worthy for careful and systemic study by both the clinician and the pathologist.

OBJECTIVES

1. To study various histopathological lesions in appendectomy specimens.
2. To analyze the proportion of various lesions in resected specimens of appendix.

MATERIALS AND METHODS

The present study was done on surgically removed appendix specimens over period of two years.

The appendectomies done primarily for appendicular pathology and those resected along with hemicolectomy procedures were excluded from this study.

All the resected specimens were initially fixed in 10% formalin. Three bits were taken from each specimen.

These included two transverse bits, one from resected end and another from body region and one longitudinal bit from the tip and were processed routinely to obtain 4 to 5 μ thick paraffin sections. For microscopic study, Haematoxylin and Eosin stain was routinely done. Periodic Acid Schiff (PAS), and Zeihl-Neelson stains were done when required.

RESULTS

During the period of study of 2 years, 420 appendectomy specimens were examined. This constituted 4.82 % of the total number of surgical specimens (8700) received during this period.

Table 1: Incidence of appendicular pathology

HP Findings	No. of case (%)Percentage
Acute inflammation	241(57.38%)
Chronic inflammation	166 (39.52%)
Tumor and tumor like lesion	9 (2.14%)
Granulomatous lesion	3 (0.71%)
Diverticulum	1(0.23%)
Total	420 (100%)

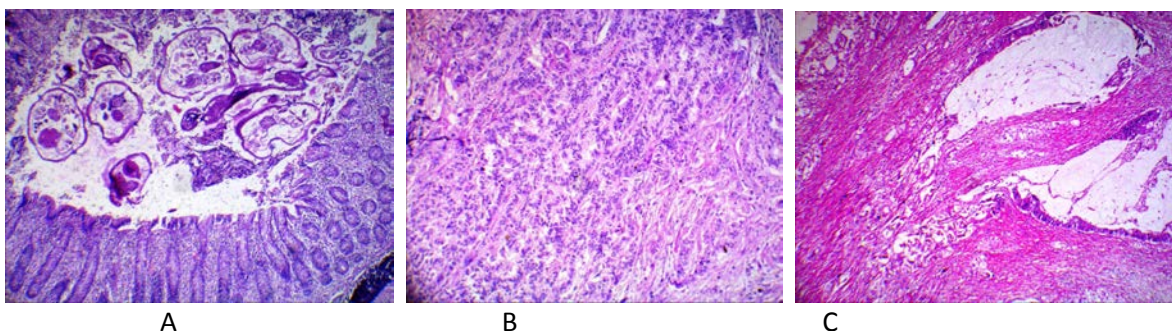
As noting the clinical findings through case records, abdominal pain was the chief complaint in all patients, next complaint was fever documented in patients and pain along with fever was documented in few patients.

The histopathological examination of 420 specimens, showed acute inflammation in 241 (57.38%) from which 6 cases were showing parasite i.e enterobius vermicularis, chronic inflammation in 166 (39.52%), tumor and tumor like lesions in 9 (2.14%), granulomatous lesion in 3

(0.71%) and diverticulum in 1(0.23%) of 420 specimen of surgically resected appendix.

Tumor and tumor like conditions includes mucocoele, carcinoid and mucinous adenocarcinoma.

Out of 420 appendectomy specimens, 256 (60.95%) were from females and 164 (39.04%) were from males. In those 154 (63.90%) were males and 87(36.90%) were females having acute inflammation, and 92 (54.42%) and 74 (44.57%) males and females showing chronic inflammation respectively.



- A. Cross section of Enterobius vermicularis in the lumen (H & E Low power)
- B. Carcinoid tumor: Nests of tumor cells involving the wall of appendix(H & E low power)
- C. Mucinous adenocarcinoma showing glands containing pale eosinophilic mucin H&E Low power.

DISCUSSION

Diseases of vermiform appendix are the commonest and apparently existing since ancient times. Acute appendicitis still remains the most important cause of acute abdominal condition, peritonitis and emergency abdominal operation.

Although mortality has decreased, the disease is still a challenge for the surgeon who is confronted with post operative complications. In addition to the findings of

acute inflammation, the excised appendix can be the site of a variety of neoplasm and unusual inflammatory conditions.

In the present study we have analyzed prospectively the incidence and type of different histopathological findings found in appendectomy specimens at our institution over a period of two years and compared the histopathological findings with the clinical diagnosis.

Table 2: COMPARISON OF INCIDENCE OF APPENDICULAR PATHOLOGY

HP finding	Zulfikari et. al., (2009) ⁷	Subedi N et. al (2011) ⁸	S Shaveta et. al.,(2014) ⁹	Present study
Acute inflammation	86.3%	91.9%	89.54%	57.38%
Chronic inflammation	8.38%	3.5%	2.5%	39.52%
Granulomatous appendicitis	3%(TB)	-	-	0.71%
Diverticulosis	1.5%	-	-	0.23%
Tumor and tumor like lesion	0.12%	0.6%	1.36%	2.14%

Our study shows incidence of acute inflammation in appendix were less comparative to all other studies however, cases of acute inflammation was common finding in our studies followed by chronic inflammation.

CONCLUSION

A prospective study was performed to determine the incidence and type of different histopathological findings in appendectomy specimens at our institution and discuss their significance in the light of the available literature.

Obstruction of the lumen is the dominant factor for acute appendicitis. Some usual etiologic factors are fecaliths and lymphoid hyperplasia. Although the symptomatology of some intestinal parasites, appendiceal neoplasms and some coexisting pathologies imitates an attack of acute appendicitis, the true nature of disease is diagnosed only through histological examination.

Some unusual or coexisting may be rarely seen in appendectomy specimens. Hence, meticulous examination and evaluation should be performed in each case.

Despite the decline in incidence of appendicitis in recent decades, the vermiform appendix continues to be frequently encountered surgical pathology specimen. Our knowledge about diseases of appendix including appendicitis, the most common disease, is far from complete. This organ therefore remains worthy of careful and systematic study both by the clinician and the pathologist

REFERENCES

1. Kumar V, Abbas A K, Nelson F, Aster J C. Robbins and cotran pathologic basis of disease.8th edition. New Delhi: Elsevier; 2011.pg 826-27.
2. Blair NP, Bugis SP, Turner LJ, MacLeod MM. Review of the pathologic diagnoses of 2,216 appendectomy specimens. Am J Surg 1993;165:618-20.
3. Machado NO, Chopra P, Pande G. Appendiceal tumour-retrospective clinicopathological analysis. Trop Gastroenterol 2004; 25: 36-39
4. Arca MJ, Gates RL, Groner JI, Hammond S, Caniano DA. Clinical manifestations of appendiceal pinworms in children:an institutional experience and a review of the literature. Pediatr Surg Int 2004; 20: 372-375.
5. Lee H Y, Jayalakshmi P, Noori S.H.S. Acute appendicitis-The university hospital experience. Med j Malaysia. 1993 Mar;48(1):17-18.
6. Williams RA, Myers P. Pathology of the appendix, Chapman and Hall medical, London; 1994.
7. I Zulfikar, T. W. Khanzada., C Sushel, A Samad. Review of the Pathologic Diagnoses of Appendectomy Specimens 2009 OCT. - DEC. ANNALS ;15(4):168-70.
8. Subedi N, Dangol US, Adhikary MB, Pudasaini S, Baral R. Acute appendicitis: A 2-year review of clinical presentation and histopathology Journal of Pathology of Nepal 2011. 1:104-07.

9. Sharma S et al. Histopathology of Appendicectomy Specimen: A 5 Year Study, Sch. J. App. Med. Sci., 2014; 2(1B):176-180.