

**A non-traditional therapeutic strategy in management of fulminant hepatic failure: histopathological and immunohistochemistry study**Farid A. Badria*¹, Atallah F. Ahmed¹, Wael M. Elsaed², Omar M. Gabre², Kamal G. Botros²¹ Department of Pharmacognosy, Faculty of Pharmacy, Mansoura University, Mansoura 35516, EGYPT² Department of Anatomy and Embryology, Faculty of Pharmacy, Mansoura University, Mansoura 35516, EGYPT

Received 02 January 2014; Accepted 18 January 2014

ABSTRACT

The present study was undertaken to evaluate the crucial role of hepatocytes transplantation in experimental model of D-galactosamine induced fulminating hepatic failure (FHF) in rat. Hepatocytes were isolated and grown from a group of apparently healthy rats. The isolated hepatocyte was characterized and cultured in vitro and transplanted in FHF rat models either alone or with cyclosporine as immunosuppressive agent. The isolated hepatocytes were cultured for 24 hours prior transplantation in the peritoneal cavity in each of infected (FHF) rat. It was observed that the high survival rate and the improvement of the liver function parameters among transplanted groups versus the non-treated ones. Histopathological and immunohistochemistry data revealed the presence of hepatocytes attached to the peritoneal covering of the abdominal organs in either a single or several layers.

Key words: *D-Galactosamine*, FHF, Cytokeratine immune stain**1. INTRODUCTION:**

Fulminant Hepatic Failure is defined as the development of hepatic encephalopathy and profound coagulopathy within 8 weeks of the onset of symptoms in patients without a preexisting liver disease (1). Despite recent therapeutic advances, fulminant hepatic failure (FHF) remains a serious clinical condition that is associated with a high mortality rate. With improvement in surgical techniques and immunological management, orthotopic liver transplantation has become the established treatment of choice for FHF and end-stage liver disease (2).

Extensive laboratory studies performed over the last three decades, and recent clinical studies have shown that hepatocyte transplantation may serve as an alternative to liver transplantation (3). The functional hepatocyte is the core of the temporary liver support. Since donor hepatocytes are limited, it is imperative to explore ways to gain functional hepatocytes (4).

Recently stem cell transplantation prompted as a new approach for treatment of liver disorders (5, 6)

The liver and spleen are the most reliable sites for hepatocytes engraftment and function (7). However the spleen is considered as the most privileged anatomical

site for hepatocytes transplantation. It can entrap a limited, but a sufficient number of hepatocytes within its sinusoids, providing conditions very similar to natural cell microenvironment. This process has been described by Mito et al. (8), by the term splenic hepatization. Also a significantly better survival of intrasplenically transplanted animals has been demonstrated, suggesting the superiority of the spleen as a site for cell implantation. However the capacity of the spleen to accommodate cells is limited.

On the other hand, peritoneal cavity is a very promising site for hepatocytes transplantation as it can be accessed by minimally invasive means and allows the injection of a greater number of cells. The attraction of this site for transplantation is based on its large capacity and easy access (9). Previous studies suggested that hepatocytes can function in ectopic sites with clinical and biochemical improvement (10). The liver and spleen are the most reliable sites for hepatocytes engraftment and function. The peritoneal cavity may also be a site for transplantation of hepatocytes, but other ectopic sites appear to be far less favorable for hepatocytes engraftment. (9)

This is an attempt to reach a non-traditional therapeutic strategy to help in management of FHF among rats with

future prospective application on human. Therefore the specified aim of this study was designed to evaluate the crucial role of hepatocytes transplantation in treating D-galactosamine induced fulminant hepatic failure (FHF) in rats.

2. MATERIALS AND METHODS:

2.1. Animals:

Seventy two adult male albino rats (Theodor Bilhars institute, Imbaba, Egypt) weighting 200- 250g, were used in this study. They were randomly divided into 5 groups.

- Group I (16 rats): control group.
- Group II (8 rats): were used for hepatocytes isolation.
- Group III (16 rats): received D-galactosamine and subjected for biochemical and histopathological assessment 24 hours after the last treatment
- Group IV (16 rats): received D-galactosamine followed by intraperitoneal hepatocytes transplantation.
- Group V (16 rats): received D-galactosamine followed by intraperitoneal hepatocytes transplantation and cyclosporine treatment

Animals of group IV and V were sacrificed at 3 and 5 days for biochemical assessment and at the 7th day after the last treatment for both biochemical and histopathological assessment.

2.2. Isolation and culture of hepatocytes:

A modification of the technique described by Seglen (11) was used for the hepatocyte isolation. The liver of a rat of group II is cannulated, perfused *in situ* with buffer and medium, excised and perfused in a closed system with Hanks' balanced salt containing 0.075% collagenase (type I, 125-250 IU/mg). The consistency of the liver becomes soft, due to digestion of the connective tissue. At this point the liver is transferred into culture medium enriched with fetal calf serum (10% bovine serum albumin at pH 7.4) and the Glisson's capsule is cut in order to obtain a crude cell suspension. Viability of the cells by trypan blue exclusion test was 90% in this experiment. The isolated cells were suspended in Eagle's MEM solution with 10% inactivated calf serum, penicillin (100 IU/ml), streptomycin (100 µg/ml), 10⁻⁶ M dexamethazone sodium phosphate and 10⁻⁸ M insulin.

The cell suspension was adjusted to be 1 x 10⁶ viable cells/0.1 ml. Inocula of 1 x 10⁶ cells/0.1 ml (culture medium) were seeded into 24 well plastic culture plates which were incubated in humidified incubator at 36.5 °C under 5% CO₂ in air for 24 hours. The viability was repeated 24 after culture it was about 90%.

2.3 Induction of fulminant hepatitis:

An animal model of FHF was created in rats of group III using D-Galactosamine (Sigma Chemical Co., St. Louis. MO. USA) intraperitoneally at a dose of 1.4 g/kg. A second identical D-galactosamine injection was administered 12 hours later.

2.4. Hepatocytes transplantation:

Hepatocytes were isolated by collagenase and cultured for 24 hours were injected in a volume of 200 µl of culture medium containing 1 x 10⁶ cells in with a 30-gauge needle connected to 1 ml syringe into the peritoneal cavity of ether anesthetized animals of group IV and V.

2.5. Biochemical and Histopathological assessment:

Heparinised blood samples were taken from living animals, centrifuged to obtain plasma. Aspartate transaminase (AST), alanine transaminase (ALT) activities, albumin and prothrombine levels in the plasma were determined using commercially available kits (Sigma chemical cost. Louis, Mo, USA).

Twenty four hours after treatment with D-galactosamine, specimens from the livers of group III and seven days after transplantation, specimens from peritoneal cavity and all abdominal viscera were of group IV and V taken from sacrificed animals immediately after death, fixed in 10% neutral formalin and processed for histological examination and stained with Hx & E, Masson's trichrome, PAS and Cytokeratin immune stains.

The survival rate

The survival rate was determined by the number of rats survived for 10 days after the beginning of the experiment to the total number of rats.

3. RESULTS:

Under defined culture environment, the freshly isolated hepatocytes attached to each other within 4h - 8h and multiple aggregates of different sizes were loosely formed and the multiplicity of the aggregates increased along with time. After 24 hours, a lot of aggregates were seen in the culture dishes. Some aggregates were also attached to each other. The free hepatocytes in culture media were examined under light microscopy without staining. The cultured hepatocytes had abundant cytoplasm as in normal ones.

3.1. Histopathological findings:

Sections of the liver of group III revealed areas of variable degrees of necrosis, parenchymal collapse with loss of the normal architecture and congestion of central veins with ballooning of hepatocytes. The ballooned cells appeared

swollen with pale granular to clear cytoplasm. The nuclei are somewhat larger than ordinary hepatocytes. Individual cell necrosis was also detected. The necrotic cells appear shrunken with dense eosinophilic cytoplasm

and pyknotic nuclei or even loss of the nuclei. (Fig. 1 and 2) The liver tissues showed small areas of focal necrosis of hepatocytes associated with perivascular lymphocytic infiltration

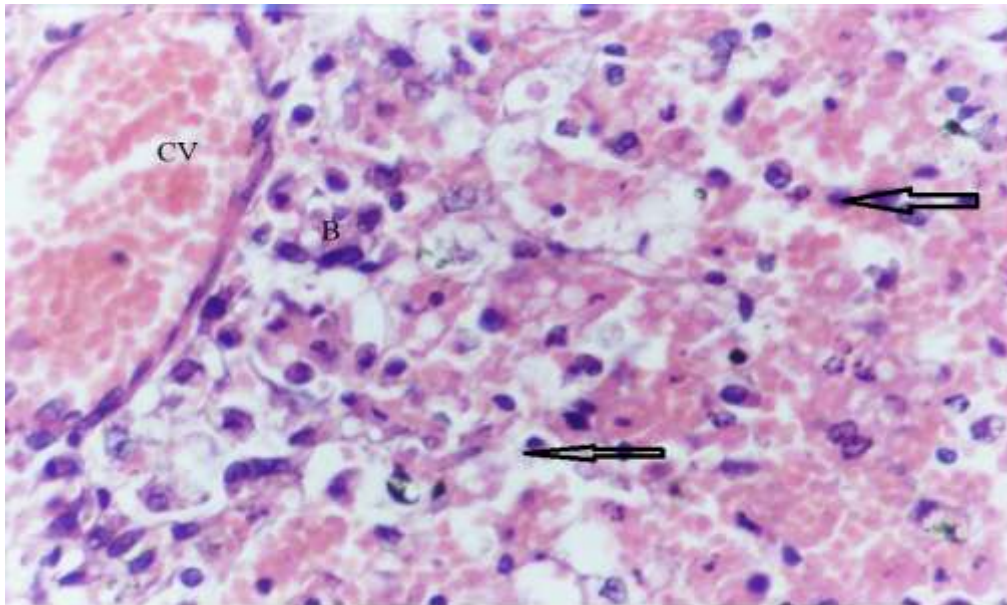


Figure 1: A photomicrograph of a section in liver of albino rat 24 hours after treatment with D-galactosamine showing areas of necrosis of variable degrees (arrows), loss of the normal liver architecture, congested central vein (CV) with perivascular lymphocytic infiltration (arrows) and ballooning of hepatocytes (B) a picture of FHF.(Hx & E stain x 400)

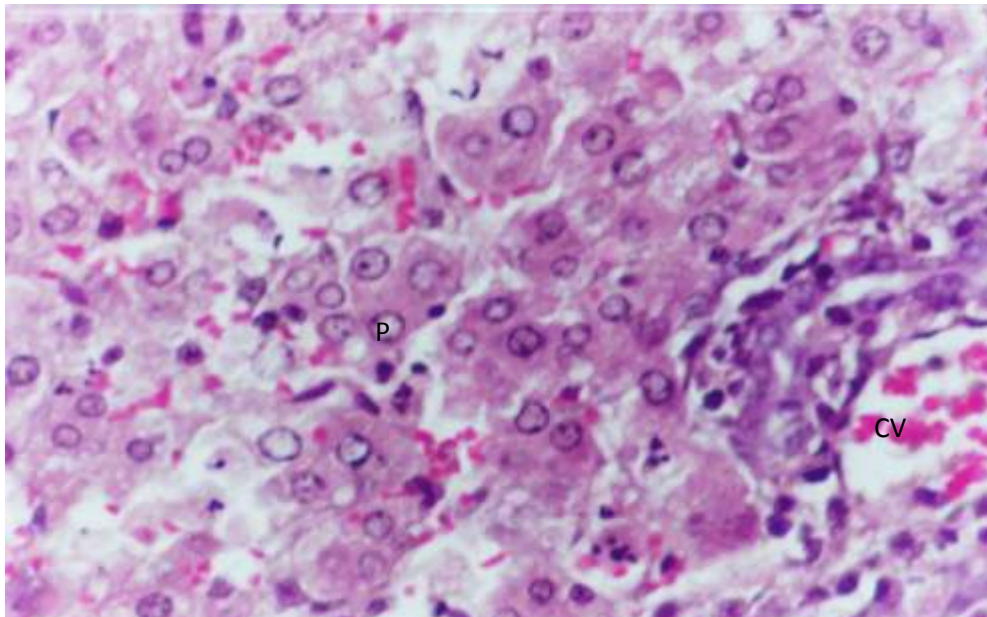


Figure 2: A photomicrograph of a section in liver of albino rat 24 hours after treatment with D-galactosamine showing congested central vein (CV) with positive PAS reaction of variable degrees. Some cells show pyknotic nuclei (P). (PAS stain x 400)

Group IV: The engrafted hepatocytes were identified by their large size, large and spherical nuclei and the distinct abundant acidophilic cytoplasm. The cells were rounded, of large number and tended to be aggregated in groups nearby the peritoneal covering. The transplanted cells were not attached to the peritoneal surface of the

abdominal organs or loosely related to it. Some cells were suspended in the nearby peritoneal cavity of these organs. All the transplanted cells showed necrotic changes in the form of pyknotic nuclei with condensed chromatin or even anucleated. The nuclei were either central eccentric or even peripheral in position. All of the

cells had abundant vacuolated cytoplasm. The lymphocytic infiltration and tissue debris (Figs.3, 4 and 5).
transplanted cells were separated by a remarkable

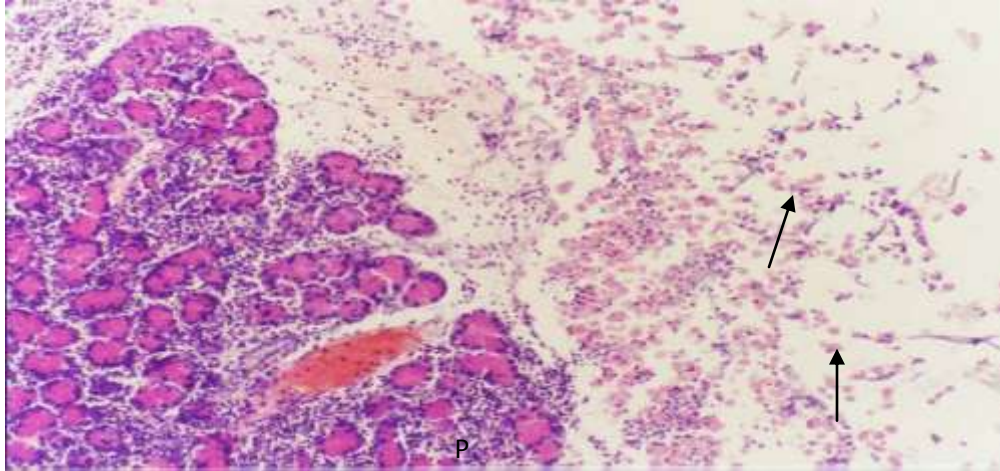


Figure 3: A photomicrograph of a section of a specimen from the peritoneum close to the pancreas (P) of a rat 7 days after intraperitoneal hepatocytes transplantation showing large number of rounded cells with acidophilic cytoplasm (arrows). (Hx & E stain x 100)

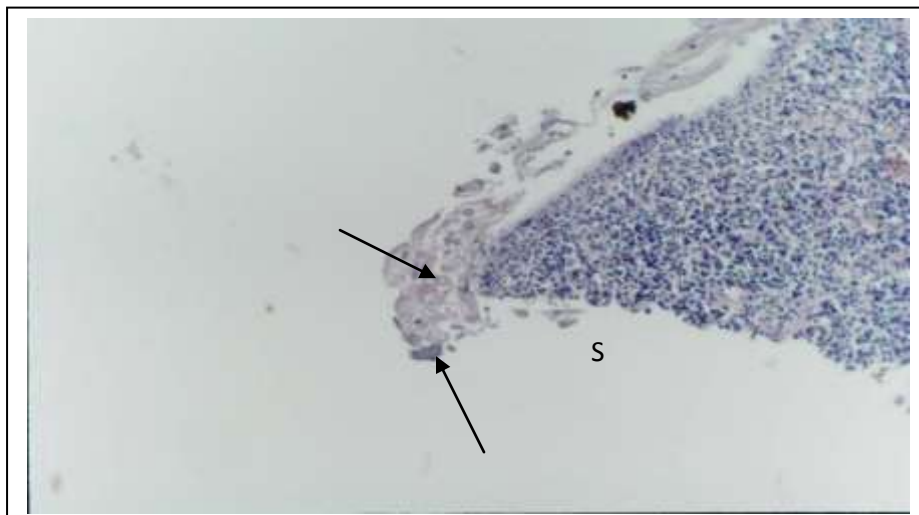


Figure 4: A photomicrograph of a section of a specimen of the spleen (S) of a rat 7 days after intraperitoneal hepatocytes transplantation showing a group of rounded cells with acidophilic cytoplasm closely related but not attached to the peritoneal covering of the spleen (arrow). (Hx & E stain x 100)

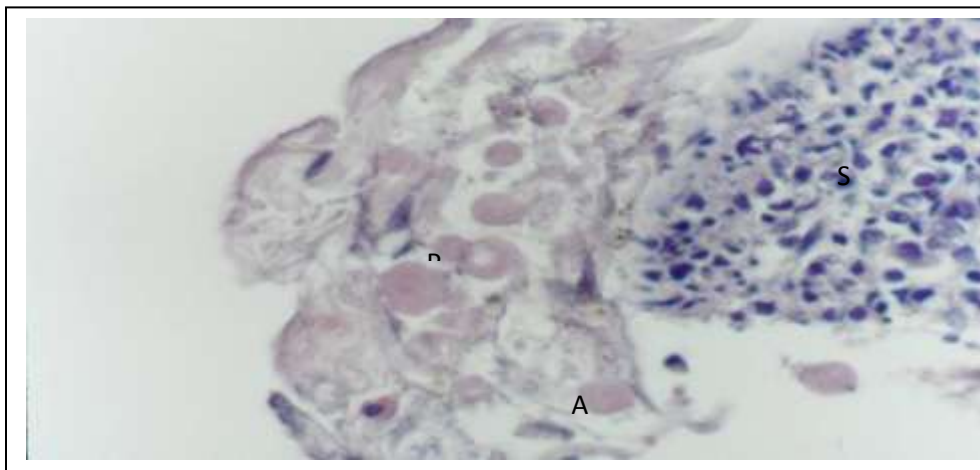


Figure 5: A photomicrograph of a higher magnification showing a group of rounded cells with acidophilic cytoplasm (arrows) closely related to the spleen (S). Most of the cells are anucleated (A) or with pyknotic nuclei (P). The transplanted cells are surrounded with multiple tissue debris. (Hx & E stain x 400)

Group V: The engrafted hepatocytes tended to be collected in groups nearby the peritoneal covering of the abdominal organs forming conglomerates which could be detected by the naked eye. The transplanted cells were large in size, with spherical nuclei and the distinct abundant acidophilic non vacuolated cytoplasm. The cells

were tightly attached to the peritoneal covering of spleen forming a single layer but sometimes more than one layer was found. The cells had abundant acidophilic cytoplasm and vesicular nuclei with prominent nucleoli. Binucleated cells were frequently observed. The cells were not surrounded with lymphocytic infiltration (Fig. 6 and 7).

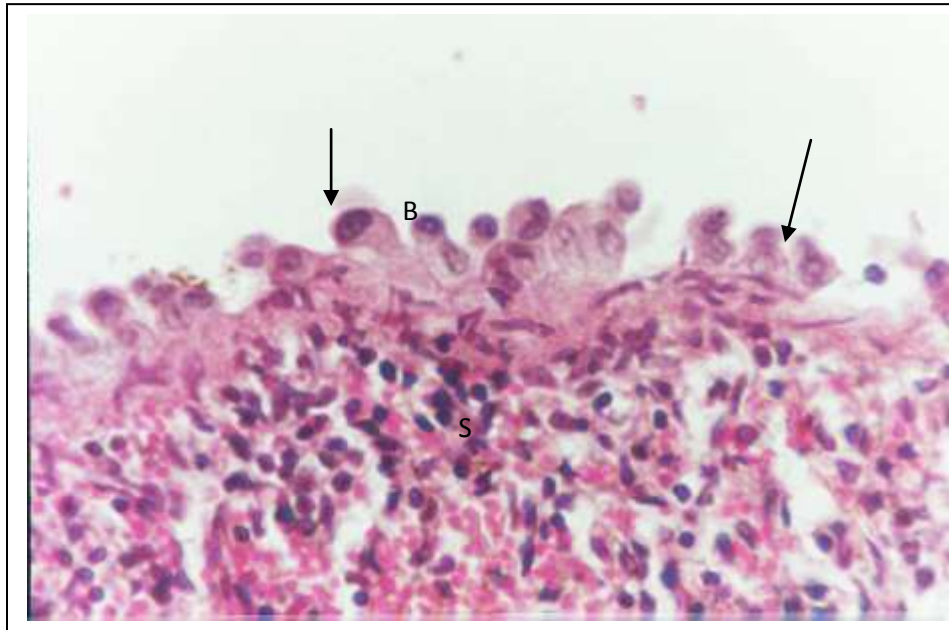


Figure 6: A photomicrograph of a section from the spleen of rat 7 days after intraperitoneal hepatocytes transplantation and treatment with cyclosporine showing rounded cells attached to the peritoneal covering of the spleen (S). The cells have abundant reddish stained cytoplasm (arrows) with vesicular nuclei and prominent nucleoli. Some cells appear binucleated (B). (HX & E stain x 400)

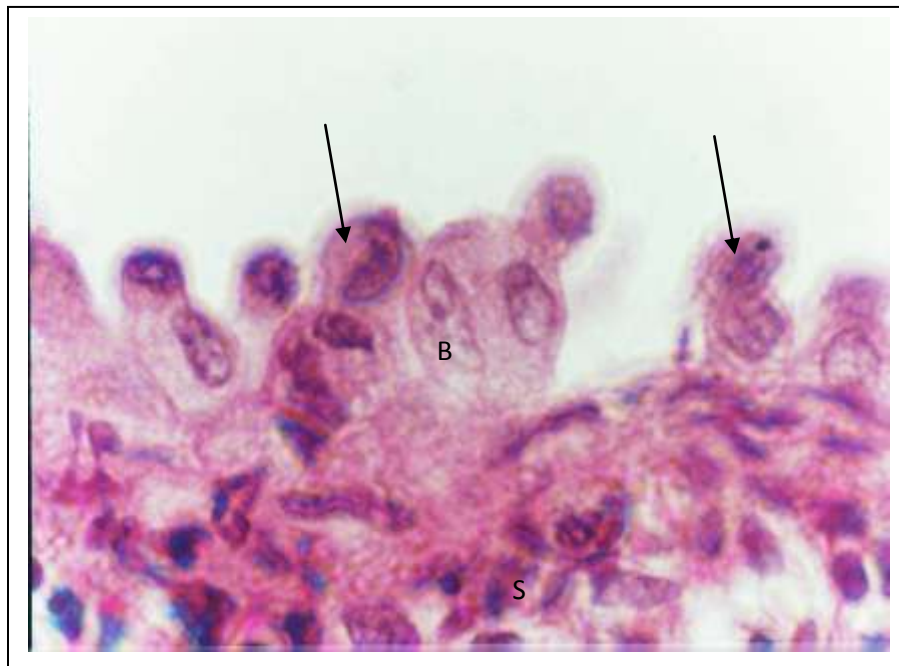


Figure 7: A photomicrograph of a higher magnification of Fig. 72 showing rounded cells attached to the peritoneal covering of the spleen (S). The cells appear with abundant red stained cytoplasm (arrows) with vesicular nuclei and prominent nucleoli. Some cells appear binucleated (B). (Hx & E stain x 1000)

3.2. Biochemical assessment:

Group III: A high increase of ALT and AST activities at 1 and 3 days after D-galactosamine administration were found. The activities of both enzymes were found near normal at the seventh day. Changes in liver albumin and prothrombin showed a significant decrease during the whole studied period.

Group IV: the increase of AST and ALT activities at one day after hepatocytes transplantation was to some degree similar to that of group III but the improvement in the ALT and AST activities at 3 days and 7 days after transplantation was more than animals of group III. Changes in liver albumin and prothrombin showed a

significant decrease at day 1 then progressively increased at days 3 to reach near the normal value at day 7 after hepatocytes transplantation.

Group V: A high increase of AST and ALT activities were found one day after transplantation (105.55 ± 4.4 and 95.21 ± 5.2). The activity of both enzymes were found higher than those of controls at day 3 (51.11± 2.4 and 47.9 ± 4.9) but lower than those of group IV. The activities of both enzymes were found near normal at day 7. Changes in liver albumin and prothrombin showed a significant decrease at day 1 then progressively increased at days 3 and 7 (Table 1).

Table 1: Liver function tests of rats treated with D-galactosamine followed by hepatocytes transplantation and cyclosporine (Group V) compared with those treated with D- galactosamine followed by hepatocytes transplantation only (Group IV) and with those treated with D-galactosamine only(group III) Versus control (Group I).

		AST	ALT	Albumin	Prothrombin	LSD _{0.05}	Sig.
Control							--
Mean ± SD		25.9 ± 4.3	29.6 ± 5.14	4.0 ± 0.78	82.67 ± 3.67	3.4681	
After one day	Group III						
	Mean ± SD	96.0 ± 5.5	70.66 ± 10.5	3.94 ± 0.35	70.0 ± 2.35	5.2150	*
	Group IV						
	Mean ± SD	101.33 ± 3.0	99.33 ± 5.59	3.53 ± 0.22	69.66 ± 5.25	7.3240	***
	Group V						
	Mean ± SD	105.55 ± 4.4	95.21 ± 5.2	3.44 ± 0.28	67.63 ± 3.43	4.2250	*
After three days	Group III						
	Mean ± SD	60.0 ± 7.3	56.33 ± 3.5	2.78 ± 0.65	63.6 ± 1.65	2.740	*
	Group IV						
	Mean ± SD	57.66 ± 3.5	52.33 ± 4.5	3.60 ± 0.70	71.0 ± 4.15	4.9730	**
	Group V						
	Mean ± SD	51.11 ± 2.4	47.9 ± 4.9	3.87 ± 0.85	77.4 ± 3.05	4.9730	**
After seven days	Group III						
	Mean ± SD	49.0 ± 6.4	45.5 ± 3.35	2.20 ± 0.45	57.5 ± 3.25	4.412	*
	Group IV						
	Mean ± SD	45.0 ± 5.75	41.0 ± 4.57	3.86 ± 1.80	79.0 ± 6.53	5.7438	**
	Group V						
	Mean ± SD	39.0 ± 3.1	37.44 ± 2.6	3.99 ± 2.56	80.54 ± 4.31	6.424	***

LSD_{0.05} (Least Significant Difference): * Significant (P<0.05), ** Significant (P<0.01) *** Significant (P<0.001).

3.3. Immunohistological examination of transplanted hepatocytes:

Group IV: Cytokeratine immune stained sections revealed clusters of large number of rounded, brownish stained cells with abundant cytoplasm with pyknotic eccentric or

even not nucleated. The cells were not attached to the peritoneum of the abdominal organs (intestine, spleen or tail of pancreas). The transplanted cells present loosely in the abdominal cavity. They were infiltrated with lymphocytic infiltration (Figs. 8-12).

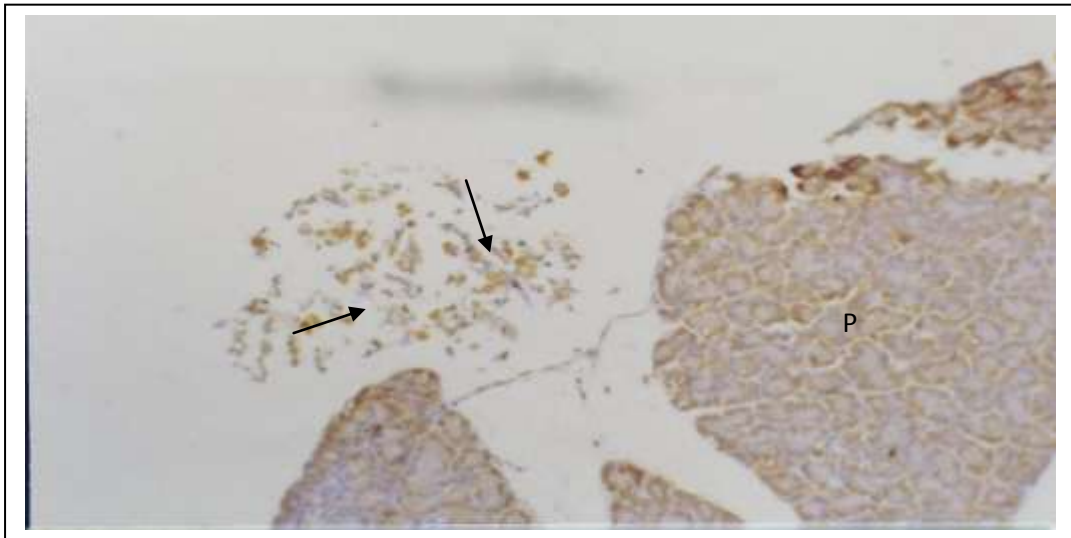


Figure 8: A photomicrograph of a section from the pancreas (P) of a rat 7 days after intraperitoneal hepatocytes transplantation showing a group of rounded cells with brownish stained cytoplasm (arrows). The cells are not attached to the pancreas. (Cytokeratine immune stain with counter Haematoxylene stain x 100)

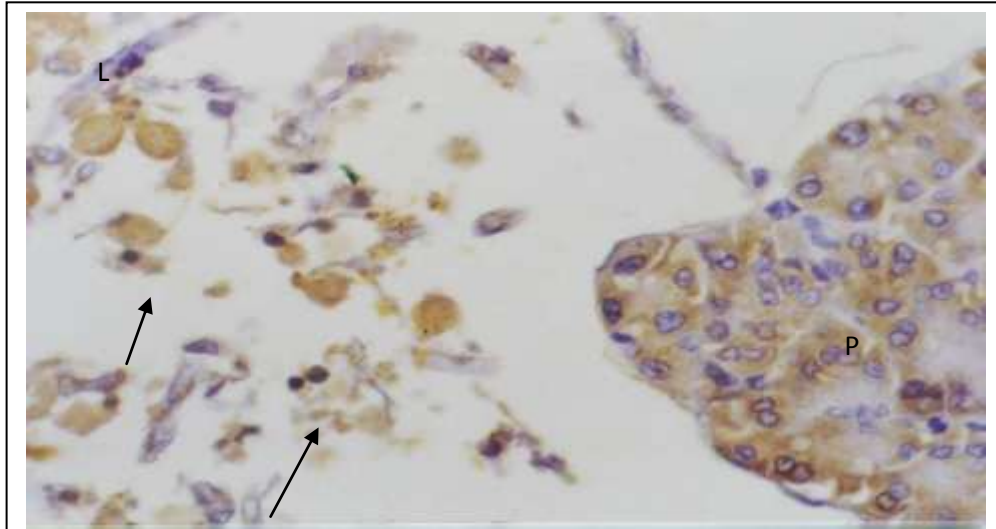


Figure 9: A photomicrograph of a higher magnification of Fig. 8 showing a group of rounded cells with brownish stained cytoplasm (arrows). The cells are surrounded with lymphocytic infiltration (L). Most of the cells are anucleated. (Cytokeratine immune stain with counter Haematoxylene stain x 400)

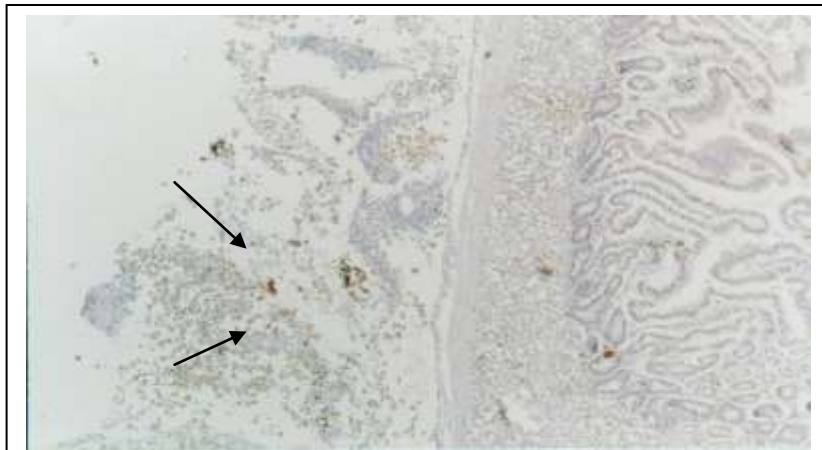


Figure 10: A photomicrograph of a section of the peritoneum close to the small intestine of a rat 7 days after intraperitoneal hepatocytes transplantation showing rounded cells with brown stained cytoplasm (arrows). The cells are not attached to the peritoneal covering of the small intestine. (Cytokeratine immune stain with counter Haematoxylene stain x 40)

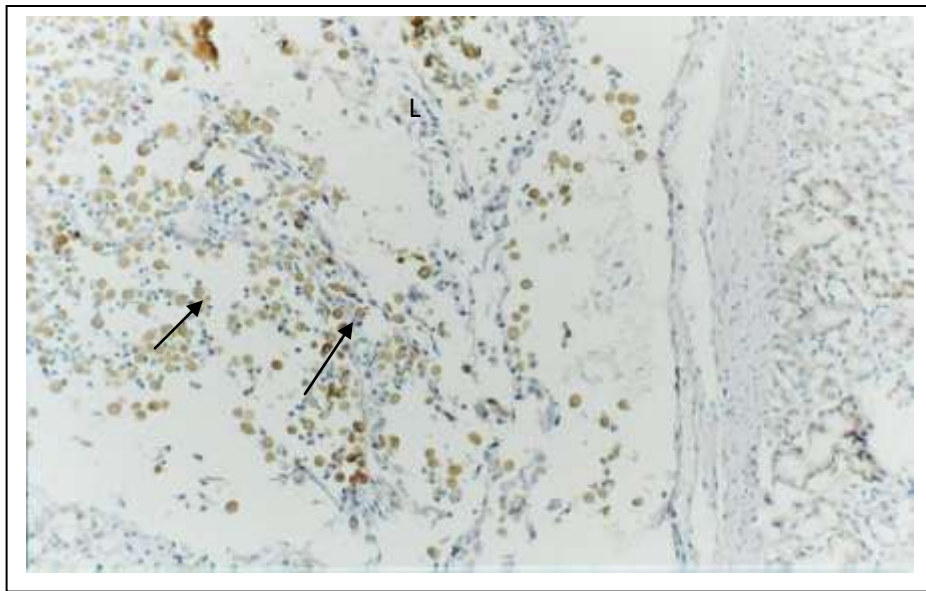


Figure 11: A photomicrograph of a section of a specimen of the peritoneum close to the small intestine of a rat 7 days after intraperitoneal hepatocytes transplantation showing rounded cells with brown stained cytoplasm (arrows). The cells are not attached to the peritoneum covering the small intestine. The cells are surrounded with multiple lymphocytic infiltration (L) and tissue debris. (Cytokeratine immune stain with counter Haematoxylene stain x 100)

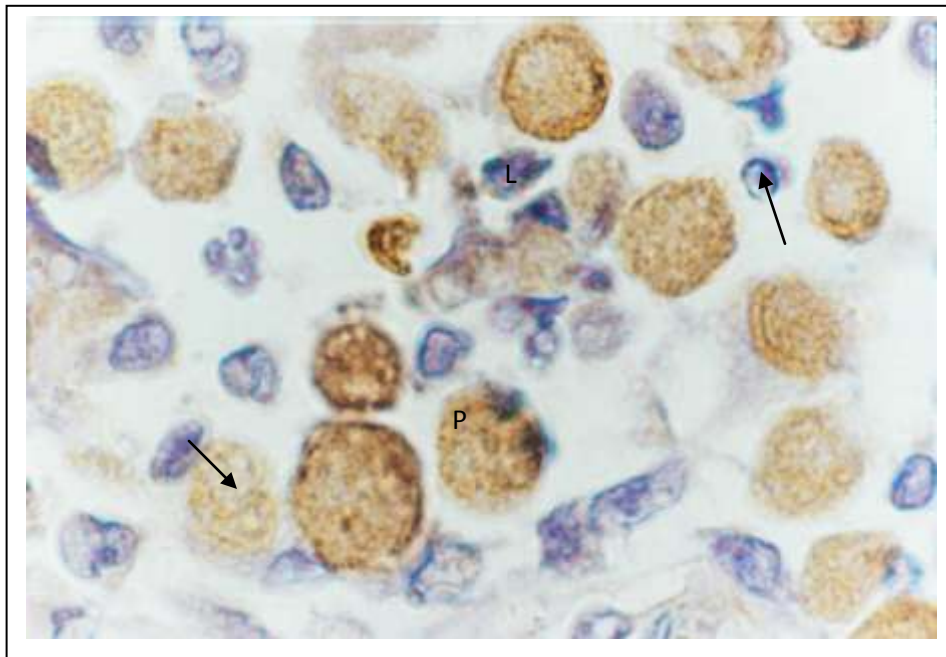


Figure 12: A photomicrograph of a section of a specimen of the peritoneum nearby the small intestine of a rat 7 days after intraperitoneal hepatocytes transplantation showing rounded cells with abundant brown stained cytoplasm (arrows). Most of the cells are anucleated. Some cells contain pyknotic nuclei (P). The cells are surrounded with multiple lymphocytic infiltration (L). (Cytokeratine immune stain with counter Haematoxylene stain x 1000)

Group V: Cytokeratine immune stained sections revealed that the engrafted hepatocytes had large size, large and spherical nuclei and the distinct abundant brownish cytoplasm. The cells were of smaller number than that of group VI. The cells were tightly attached to the peritoneal covering of spleen

(Figs 13-18) a single layer but some times more than one layer was found. Most of the detected cells were rounded, oval or polygonal. The cells had vesicular bluish stained nuclei with prominent nucleoli. Binucleated cells were frequently observed.

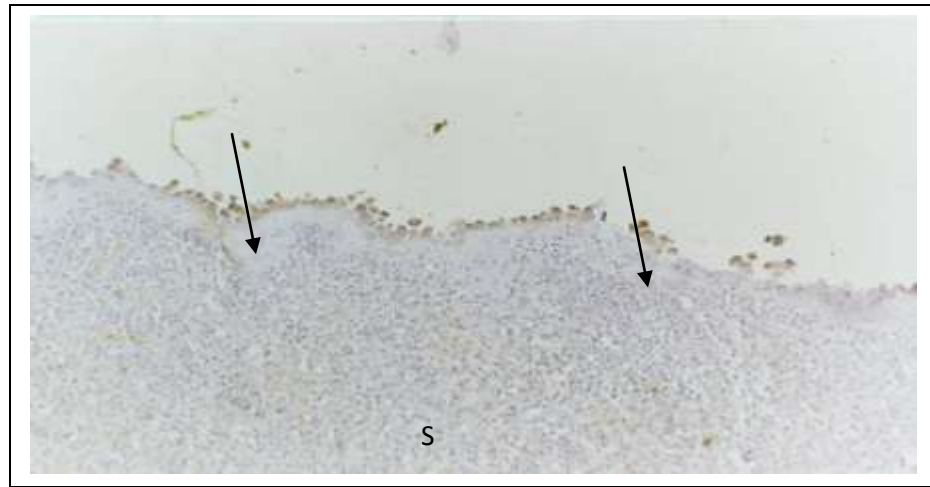


Figure 13: A photomicrograph of a section of from the spleen of rat 7 days after intraperitoneal hepatocytes transplantation and treatment with cyclosporine showing the interaperitoneally transplanted cells attached to the peritoneum of the spleen (S). The cells form a single interrupted row of rounded or polygonal brownish cells (arrows). (Cytokeratine immune stain with counter Haematoxyline stain x 100)

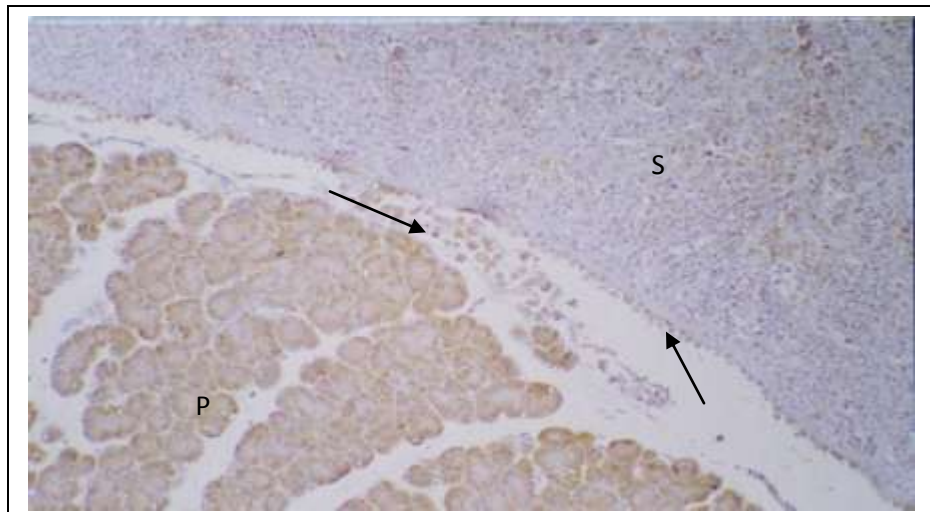


Figure 14: A photomicrograph of a section from the abdominal organs of rat 7 days after intraperitoneal hepatocytes transplantation and treatment with cyclosporine showing the transplanted cells attached to the peritoneal covering of the spleen (S) and loosely attached to the pancreas (P). The cells have brownish stained cytoplasm (arrows). (Cytokeratine immune stain with counter Haematoxyline stain x 100)

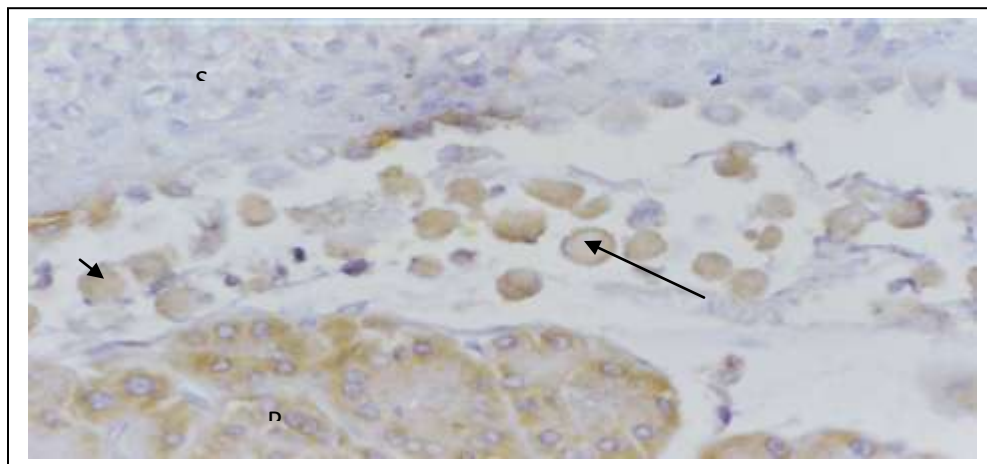


Figure 15: A photomicrograph of a higher magnification showing the interaperitoneally transplanted cells attached to the peritoneal covering of the spleen (S) and loosely attached to the pancreas (P). The cells have brownish stained cytoplasm (arrows). The loosely attached cells are anucleated. (Cytokeratine immune stain with counter Haematoxyline stain x 400)

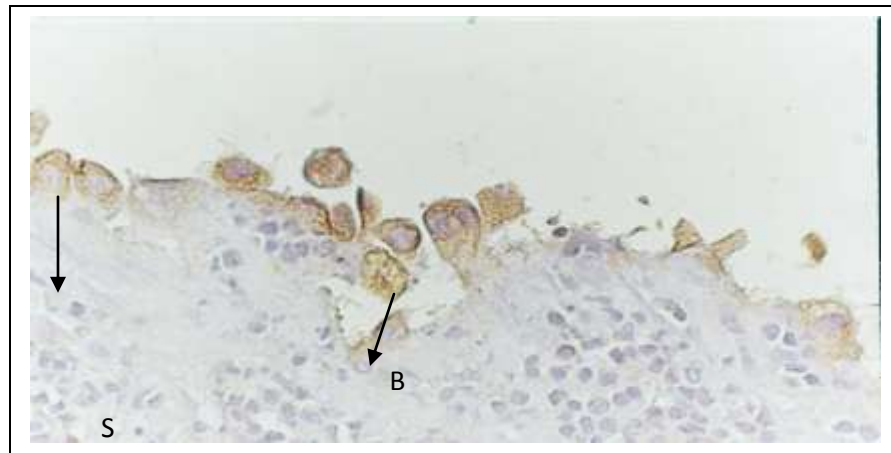


Figure 16: A photomicrograph of a section from the spleen of rat 7 days after intraperitoneal hepatocytes transplantation and treatment with cyclosporine showing the transplanted cells attached to the peritoneum of the spleen (S). The cells appear rounded or polygonal with abundant brown stained cytoplasm (arrows). The nuclei are vesicular with prominent nucleoli. Some cells are binucleated (B) (Cytokeratine immune stain with counter Haematoxyline stain x 400)

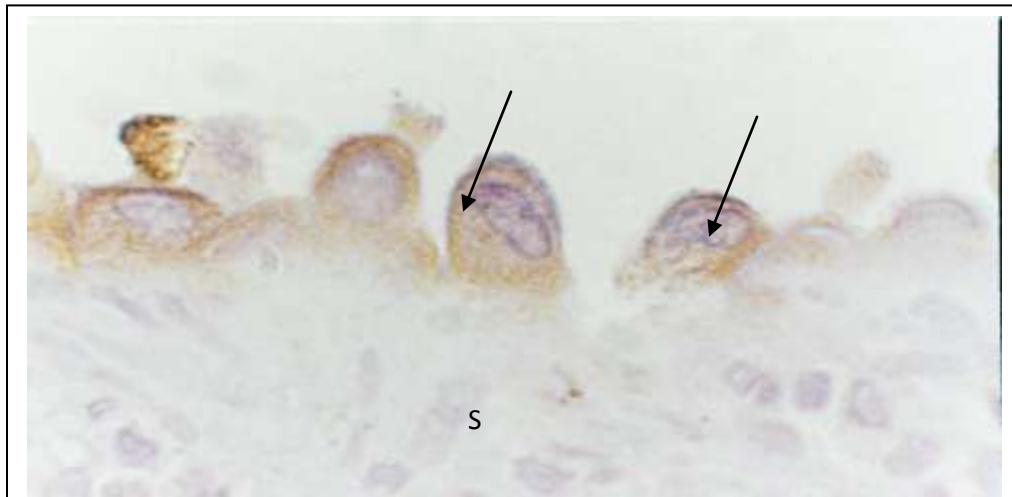

Figure 17: A photomicrograph of a section from the spleen of rat 7 days after intraperitoneal hepatocytes transplantation and treatment with cyclosporine showing the transplanted cells attached to the peritoneum of the spleen (S). The cells form a single row and appear rounded or polygonal with abundant brown stained cytoplasm (arrows). The nuclei are vesicular with prominent nucleoli. (Cytokeratine immune stain with counter Haematoxyline stain x 1000)

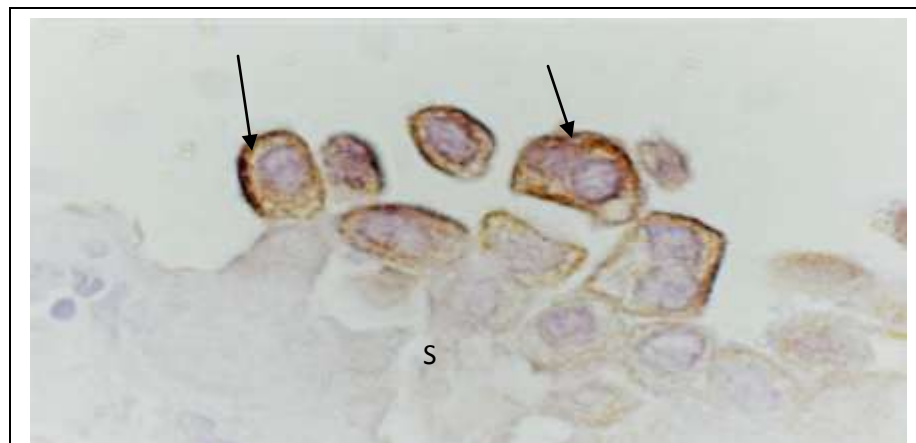


Figure 18: A photomicrograph of a section from the spleen of rat 7 days after intraperitoneal hepatocytes transplantation and treatment with cyclosporine showing the transplanted cells attached to the peritoneum of the spleen (S). The cells form more than one row and appear rounded or polygonal with abundant brown stained cytoplasm (arrows). The nuclei are vesicular with prominent nucleoli. (Cytokeratine immune stain with counter Haematoxyline stain x 1000)

Survival rate: At the 10th day survival rate in group III was 10%, 40% in group IV and 80% in group V.

4. DISCUSSION:

Hepatocytes transplantation has been studied in animal models of liver failure since the early 1970s. Various experimental techniques have been described to evaluate hepatocytes transplantation (12). However, most of the reported studies either offered indirect evidence of function of transplanted liver cells or used experimental animal models of liver injury (i.e., D-galactosamine-treated rats) that produced results difficult to interpret or reproduce owing to the variable degree of liver injury inflicted. Transplantation of hepatocytes has been shown to significantly improve the survival of animals with both chemically and surgically induced acute liver failure.

The free isolated hepatocytes after culture for 24 hours were prepared for transplantation. Various anatomical sites for hepatocytes implantation such as native liver, spleen, peritoneal cavity, kidney, lung, pancreas and fat pads have been investigated by different teams since the introduction of the method, but their results are not conclusive due to the great methodological diversity. (13).

The most important factor affecting clinical hepatocytes transplantation is a lack of donor availability. The number of livers available for hepatocytes isolation and liver transplantation is limited. Unfortunately, fatty livers do not consistently yield cells of good quality or provide cells in sufficient number to transplant. The ability to preserve and bank hepatocytes would allow pooling of cells from multiple donors to increase cell numbers for transplantation (14).

Theoretically, the intraperitoneal route has many advantages, such as easy accessibility and great capacity for cells implantation. However, the major disadvantage of intraperitoneal route was the inability of injected cells to promptly engraft and thus to receive an adequate vascular supply. This led to cell death in three days following transplantation (13). To overcome this limitation, Demetriou et al., (10) introduced the technique of cell attachment on collagen-coated dextran-microcarriers, prior to transplantation.

It seems highly possible that the recent advances in various fields, such as the development of new biomaterials and especially the introduction of humoral factors accelerating the process of neovascularization, may overcome the current limitations of the intraperitoneal hepatocytes transplantation (15).

Te velde et al. (18) compared intrasplenic and intraperitoneal hepatocytes transplantation, in a model of liver ischemia-induced failure. A significantly better survival of intrasplenically transplanted animals has been demonstrated, suggesting the superiority of the spleen as a site for cell implantation in this experimental model. Intraperitoneal hepatocytes failed to promptly engraft and provided a delayed and probably useless liver support.

In the present study the survival rate in group VI was 40% whereas in the controls (group III) was 10%. Statistically significant difference in the survival rate between transplanted groups and the controls was proven.

Although, Charalampos et al. (15) stated that isolated hepatocytes do not anchor or survive following direct injection into the peritoneal cavity. However prolonged survival has been demonstrated following encapsulation of hepatocytes with microcarriers. Also, Mai et al. (19) stated that intraperitoneal delivery of nonencapsulated fresh hepatocytes did not improve survival of mice with FHF, indicating a rapid loss of transplanted cells, due to innate or humoral rejection mechanism.

However, Intraperitoneal injections of hepatocytes into rats with fulminant hepatic failure induced by D-galactosamine led to improved survival despite the fact that donor liver cells did not repopulate the liver (12). This finding suggests that hepatocytes can function in ectopic sites with some clinical effectiveness.

An improvement in the AST and ALT activities were observed in this study at 3 days and 7 days after hepatocytes transplantation in animals treated with D-galactosamine (group VI) than that of the animals treated with D-galactosamine without hepatocytes transplantation (group III). At day 7 the activities of both enzymes were found near normal (41.0 ± 4.57 and 45.0 ± 5.75 respectively). Changes in liver albumin and prothrombin showed a significant decrease at day 1 then progressively increased at days 3 to reach near the normal value at day 7 after hepatocytes transplantation. The survived rats up to the 7th day showed normal biochemical and histological parameters independently of their previous therapy. These survival data and laboratory findings are highly suggestive of the presence of a "crucial period" during which liver support measures must be initiated. Reversal of hepatic damage seems to be due initially to the direct action of engrafted hepatocytes during this "crucial period" and subsequently to the host liver recovery, taking place in all survivors

beyond this period, independently of their initial treatment.

Cell aggregates could be macroscopically detected on the peritoneal covering of stomach and spleen. Histological examination of sections from these aggregates revealed the presence of hepatocytes which, were identified by their large size, large and spherical nuclei and the distinct abundant acidophilic cytoplasm. The cells tended to be collected in groups nearby the peritoneal covering. The transplanted cells were not attached to the peritoneal surface of the abdominal organs or loosely related to it. Some cells were suspended in the nearby peritoneal cavity of these organs. All the transplanted cells showed necrotic changes. They had pyknotic nuclei with condensed chromatin. The nuclei were either central eccentric or even peripheral in position. The number of the engrafted hepatocytes observed in histologic sections varied from a section to another. The transplanted cells were separated by a remarkable lymphocytic infiltration and tissue debris. No collagenous fibers could be detected in between the transplanted cells.

Cytokeratine immune stain was used as a specific stain. It revealed clusters of large number of rounded, brownish stained cells with abundant cytoplasm and pyknotic eccentric nuclei or even not nucleated.

Cyclosporine was well tolerated and effective as an immunosuppressive drug. Because of its long half-life and prolonged effect on circulating T cells, cyclosporine could potentially be used in future immunosuppressive regimens to minimize dependence on more toxic agents (17).

The survival rate in group V (animals treated with D-galactosamine followed by hepatocytes transplantation and cyclosporine) was 80% whereas in the group VI (in animals treated with D-galactosamine followed by hepatocytes transplantation) was 40%. Statistically significant difference in the survival rate between both groups was proven.

Achilis et al., (17) proved the presence of prolonged duration of increased plasma albumin levels and increased survival in cyclosporine treated NAR rats recipients. They suggested that cyclosporine is efficacious in inhibiting rejection of the transplanted hepatocytes.

The high survival rate and the improvement of the laboratory findings are highly suggestive of the presence of functioning hepatocytes. Reversal of hepatic damage seems to be due initially to the direct action of engrafted hepatocytes subsequently to the host liver recovery. This

can be proofed by the improvement in the liver function after administration of cyclosporine.

Clinical and biochemical improvements have been reported in several studies of humans with fulminant hepatic failure treated with intraperitoneal hepatocytes transplantation (12).

The survival of the transplanted cells in their new habitat depends on development of new blood vessels; however the examined histological sections did not reveal neovascularization mostly due to the short time of the experiment which needs to be proved in further studies.

REFERENCES:

1. Nyamathulla P., Aleem A. K., Subramani B., Mohammed A. H., Ravindra B., Samuel A. Hiroshi Y., Yuichi M. and Habibullah C.M. (2008): Intraperitoneal transplantation of hepatocytes embedded in thermoreversible gelatin polymer (mebiol gel) in acute liver failure rat model.
2. Bismuth, H., Samuel, D., Castaing, D., Adam, R., Saliba, F., Johann, M., Azoulay, D., Ducot, B., and Chiche, L. Orthotopic liver transplantation in fulminant and subfulminant hepatitis. The Paul Brousse experience. *Ann. Surg.* 222: 109, 1995.
3. Hughes, R. D.; Mitry, R. R. and Dhawan, A (2012) Current Status of Hepatocyte Transplantation. *Transplantation*: 93 (4) 342–347
4. Fox, I.J and Chowdhury, J.R. (2004): Hepatocyte transplantation. *American journal of transplantation* 4: 7-13.
5. Xiao- lei, S.H.; Yu- dong; Qiang, L.I.; Ting, X.I.E.; Zhang- hua; Lei- lei; Lei Li and Yi- tao. (2005): Hepatocyte- like cells from directed differentiation of mouse bone marrow cells in vitro. *Acta Pharmacologica Sinica* 26:469-476.
6. Brezillon, N., Kremsdorf, D., and M. C. Weiss, Cell therapy for the diseased liver: from stem cell biology to novel models for hepatotropic human pathogens. *Dis. Model. Mech.*, September 1, 2008; 1(2-3): 113 – 130.
7. Agarwal, S., Holton, K. L. and R. Lanza, Efficient Differentiation of Functional Hepatocytes from Human Embryonic Stem Cells *Stem Cells*, May 1, 2008; 26(5): 1117 - 1127.
8. Mito, M.; Kusa, T.O.; Karwre, N and Ebata, H. (1978): Hepatocellular transplantation morphological study on rat hepatocytes transplanted into rat spleen. *Gastroenterol Jpn* 13 (6): 480-490.
9. Demetriou, A.A.; Levenson, S.M. and Novitoff, P.M. (1986): Survival, organization and function of

- microcarrier-attached hepatocytes transplanted in rat. *Proc Natl Acad Sci USA* 83: 7475-7479.
10. Strom, S.C.; Chowdhury, J.R and Fox, I. J. (1999): Hepatocyte transplantation for the treatment of human disease. *Semin. Liver Dis.* 19: 39- 48.
 11. Seglen, P.O. (1976): Preparation of isolated rat liver cells. *Cell Biol.* 13: 29-83.
 12. Makowka, L.; Lee, G.; Cobourn, C.S.; Farber, E.; Falk, J.A and Falk, R.E. (1986): Allogeneic hepatocyte transplantation in the rat spleen under cyclosporine immunosuppression. *Transplantation* 42:537- 541.
 13. Makowka, L.; Falk, R.E. and Rotstein, L.E. (1980): Reversal of experimental acute hepatic failure in the rat. *J Surg Res* 29: 479-87.
 14. Charalampos, P.; Despina, P.; Maria, D.; Athena, P. and Ismini, D. (2004): Management of carbon tetrachloride induced acute liver injury in rats by syngenic hepatocytes transplantation in spleen and peritoneal cavity. *World J Gastroenterol*, 10: 2099-2102.
 15. Runge, D.; Michalopoulos, G.K.; Strom, S.C and Runge, D.M. (2000): Recent advances in human hepatocyte culture systems. *Biochem Biophys Res Commun* 274: 1-3.
 16. Henne-Bruns, D.; Krunger, U and Lieese, W. (1991): Intra-peritoneal hepatocyte transplantation: morphological results. *Virchows Arch A Pathol Ant Histopathol* 419: 45-50.
 17. Te velde, A.A.; Oshram, P.R. and Crek, M.C. (1992): Three different hepatocyte transplantation techniques for enzyme deficiency disease and acute hepatic failure. *Artif Organ*: 522-526.
 18. Mai, G.; Huy, N.T.; Morel, P.; Mei, J.; Bosco, D.; Berney, T.; Majno, P.; Mentha, G.; Trono, D. and Buhler, L.H. (2005). Treatment of Fulminant Liver Failure by Transplantation of Microencapsulated Primary or Immortalized Xenogeneic Hepatocytes. *Transplantation Proceeding*. 37: 527-529.
 19. Achillis, A.; Demetrescu, S.; Stanly, M.; Levenson, P. and Jayanata Roy (1986): Survival, organization, and function of microcarrier-attached hepatocytes transplanted in rats. *Proc. Natl. Acad. Sci. USA.* 83: 7475-7479.